

David Gozal, MD, MBA, PhD

**Professor and Dean
Vice President Health Affairs**

Clinical Cases



MARSHALL UNIVERSITY®
Joan C. Edwards School of Medicine



Case 1

3 year old boy

Loud snoring

Recurrent night terrors

Allergic rhinitis

Grumpy and difficult to arouse in morning

Past medical history: RSV bronchiolitis at age 2 weeks

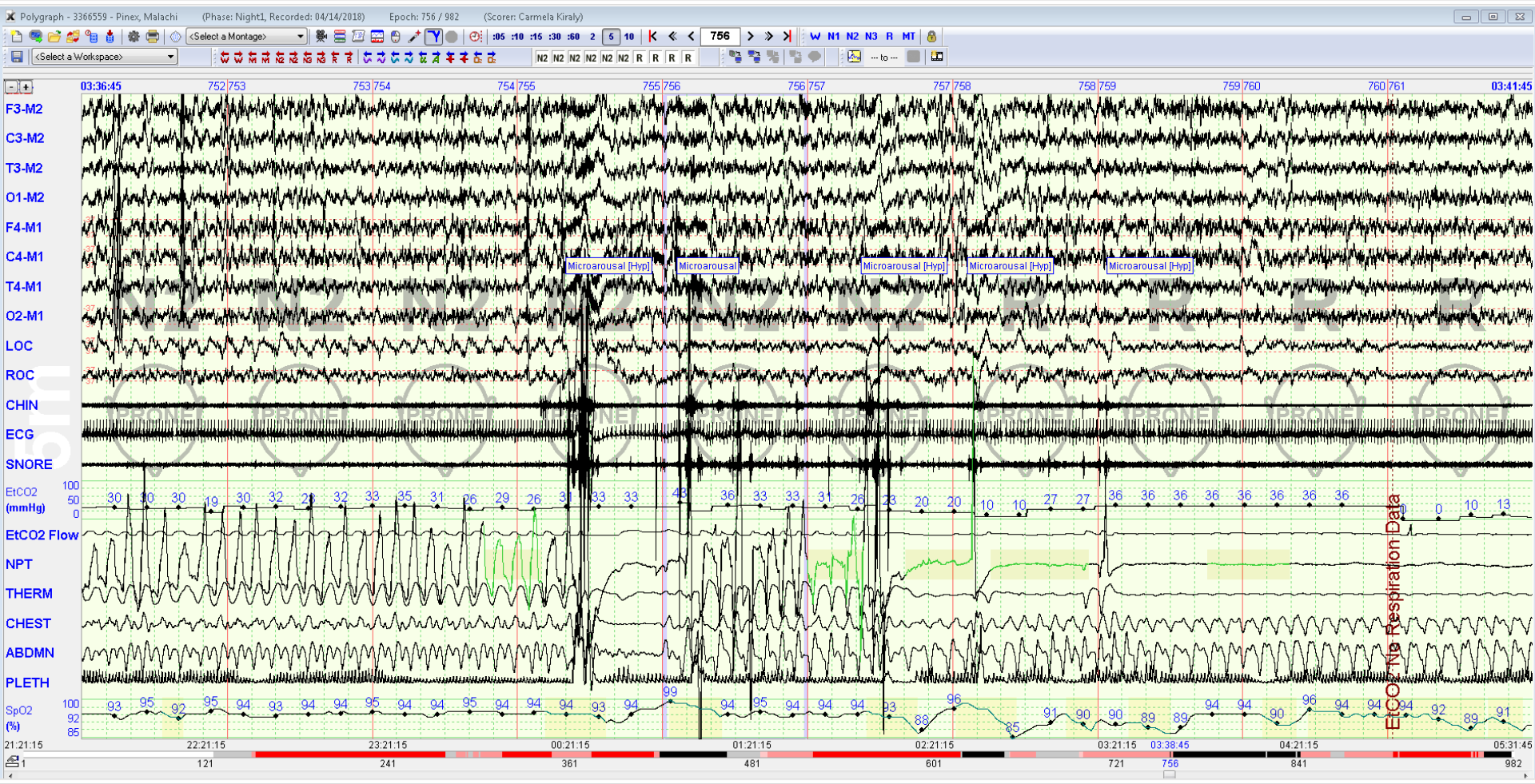Family History - negative

Physical exam:

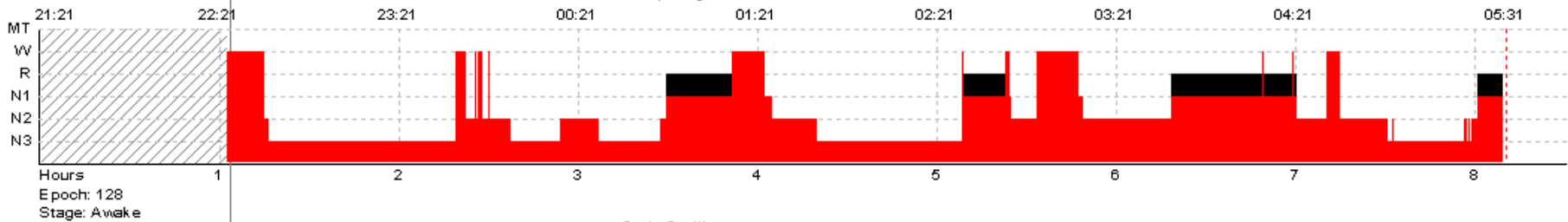
Normal BMI

Large tonsils +3; minimal retrognathia

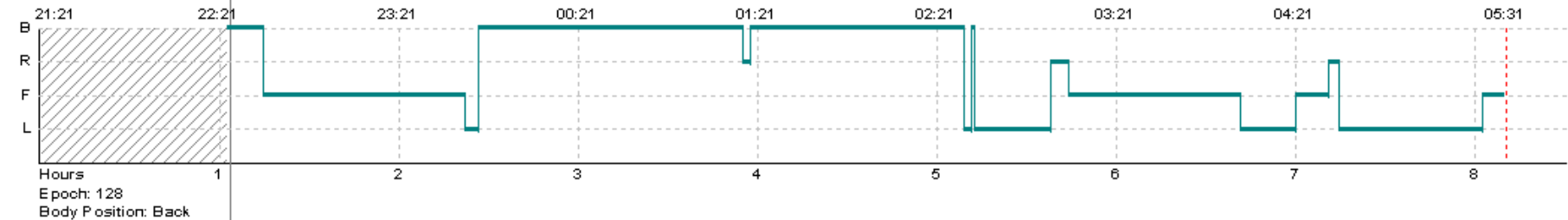
Limited nasal airflow



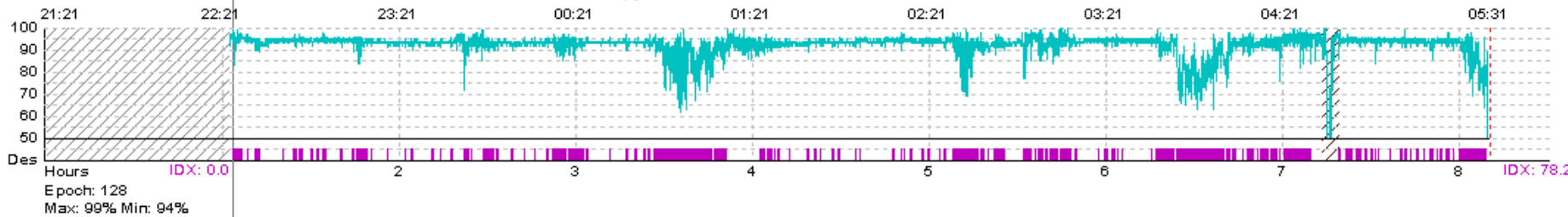
Sleep Stages



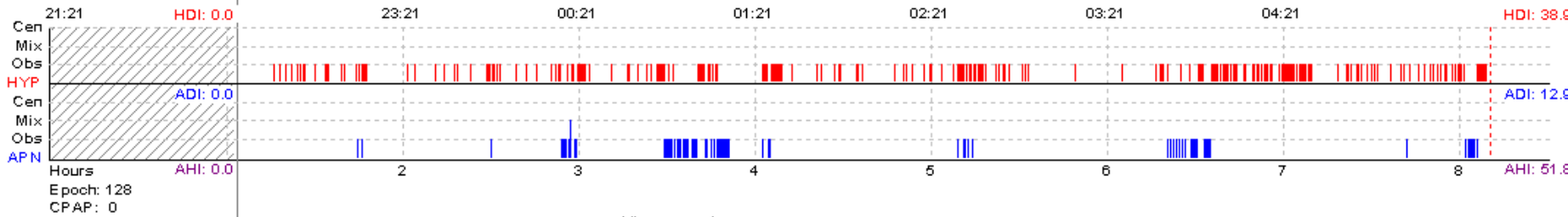
Body Position



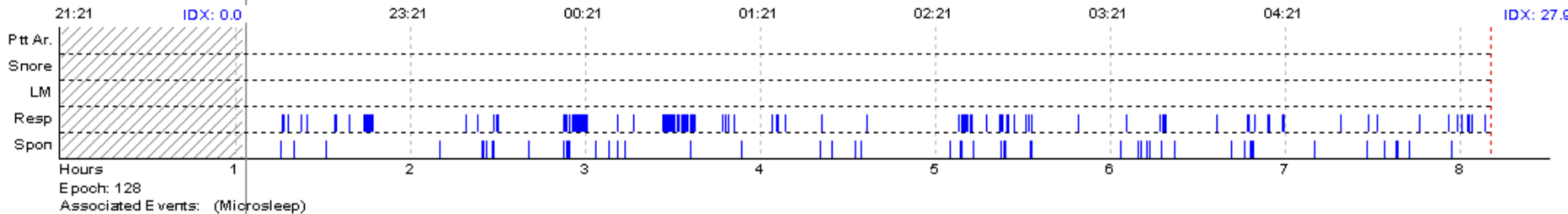
Oxygen Saturation



Apneas/Hypopneas



Microarousals



OAHI: 25.8/hrTST

ODI3%: 22.2/hrTST

Resp Arousal Index: 13.5/hrTST

Treatment: Tonsillectomy & Adenoidectomy
with inpatient admission after surgery for
cardiorespiratory monitoring

Repeat sleep study 12 weeks later - normal

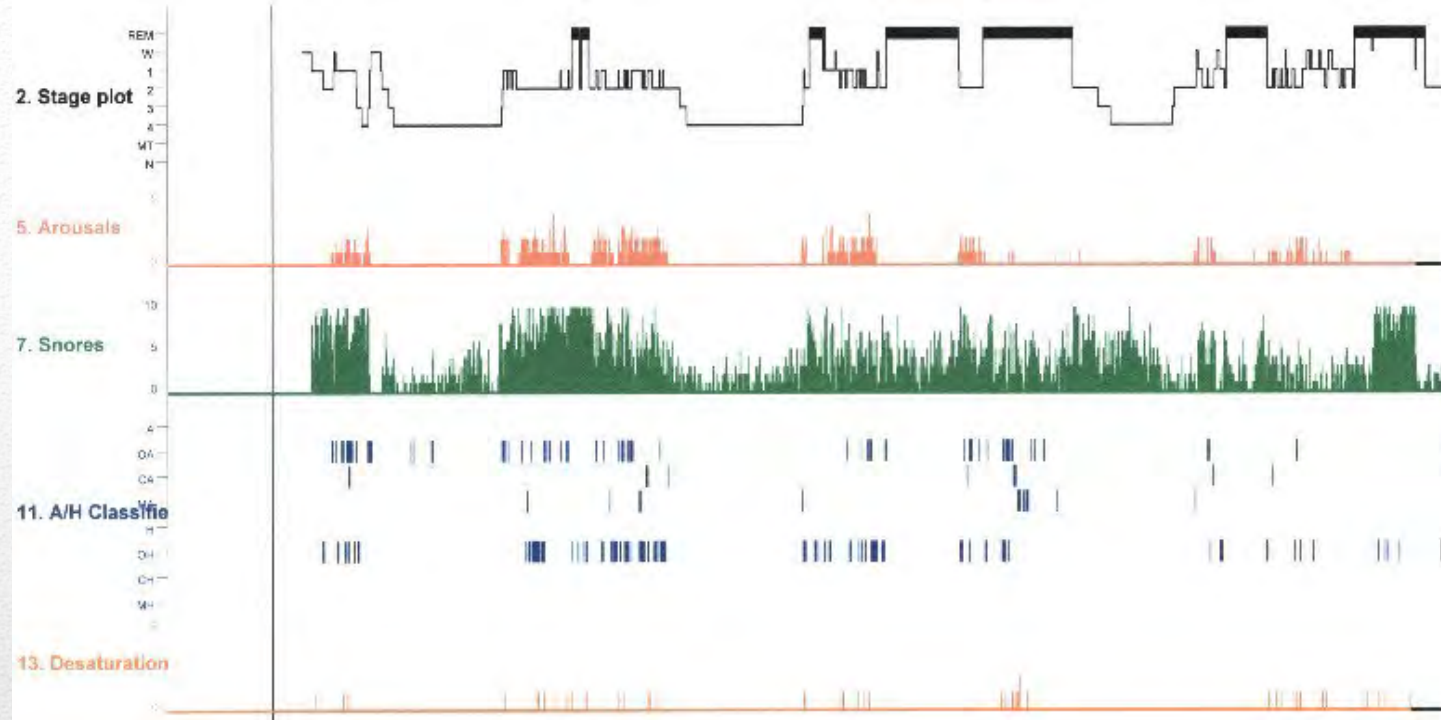
Case 2

12 year old African American Boy
Snoring loud
Daytime Tiredness
Doing poorly at school
Disruptive behavior/aggressive

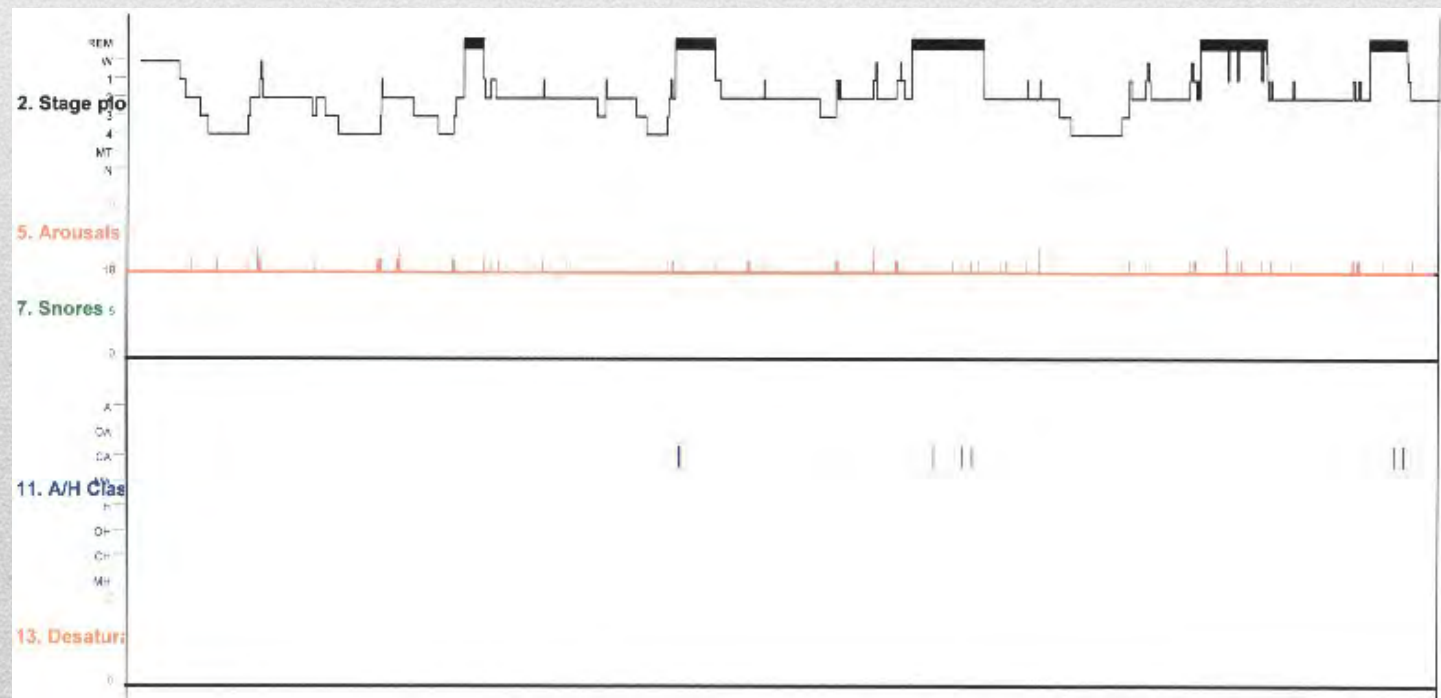
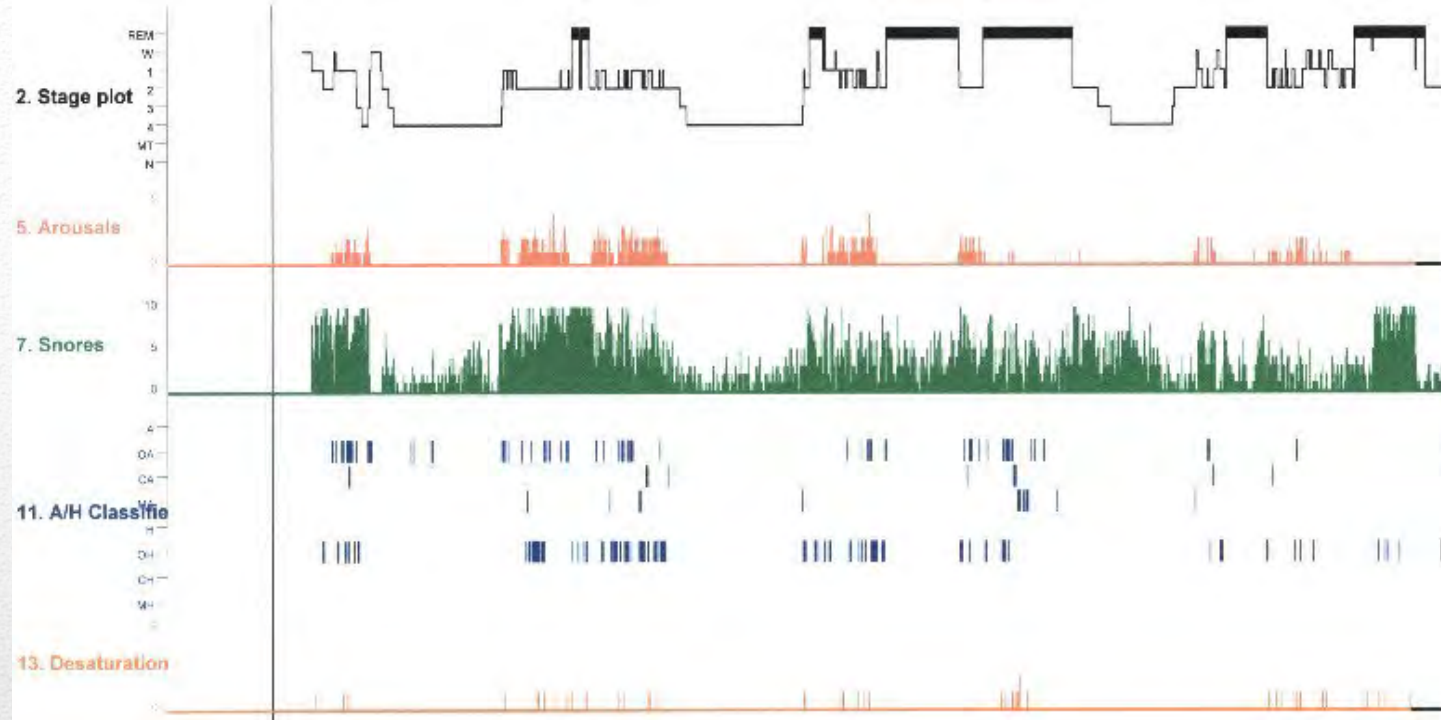
Family – OSA in father – not treated

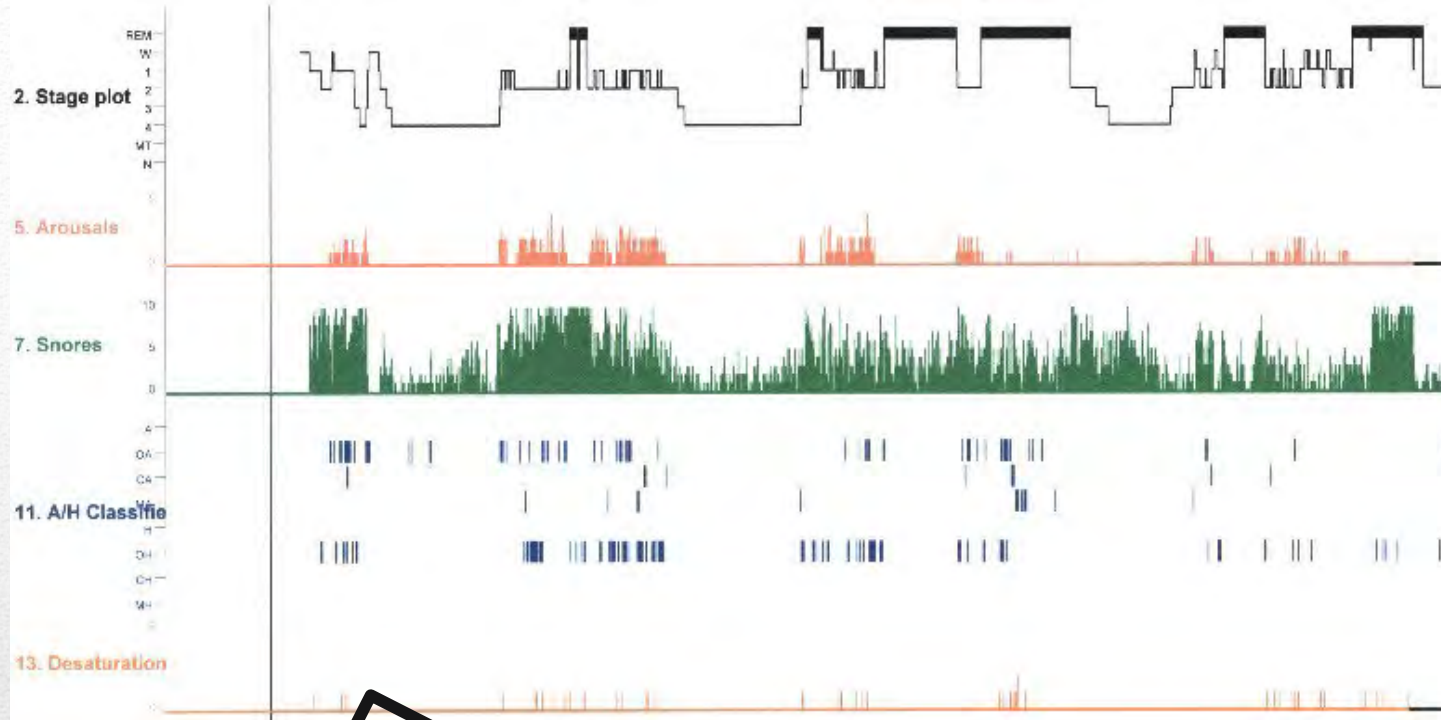
Physical Exam:

Tonsils +3; moderate retrognathia; narrow palate
Mallampati +3; normal nasal airflow



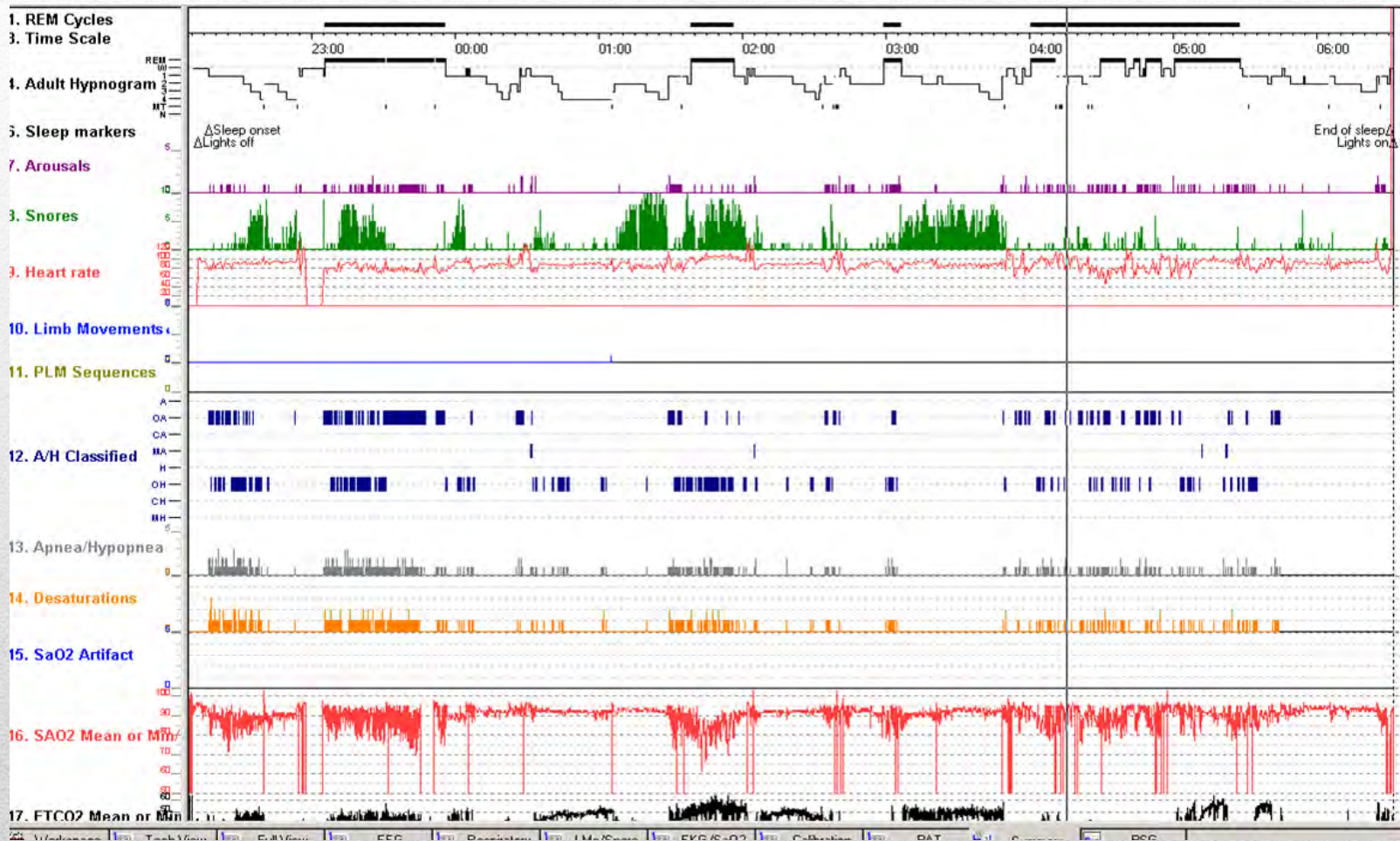
Tonsillectomy and adenoidectomy



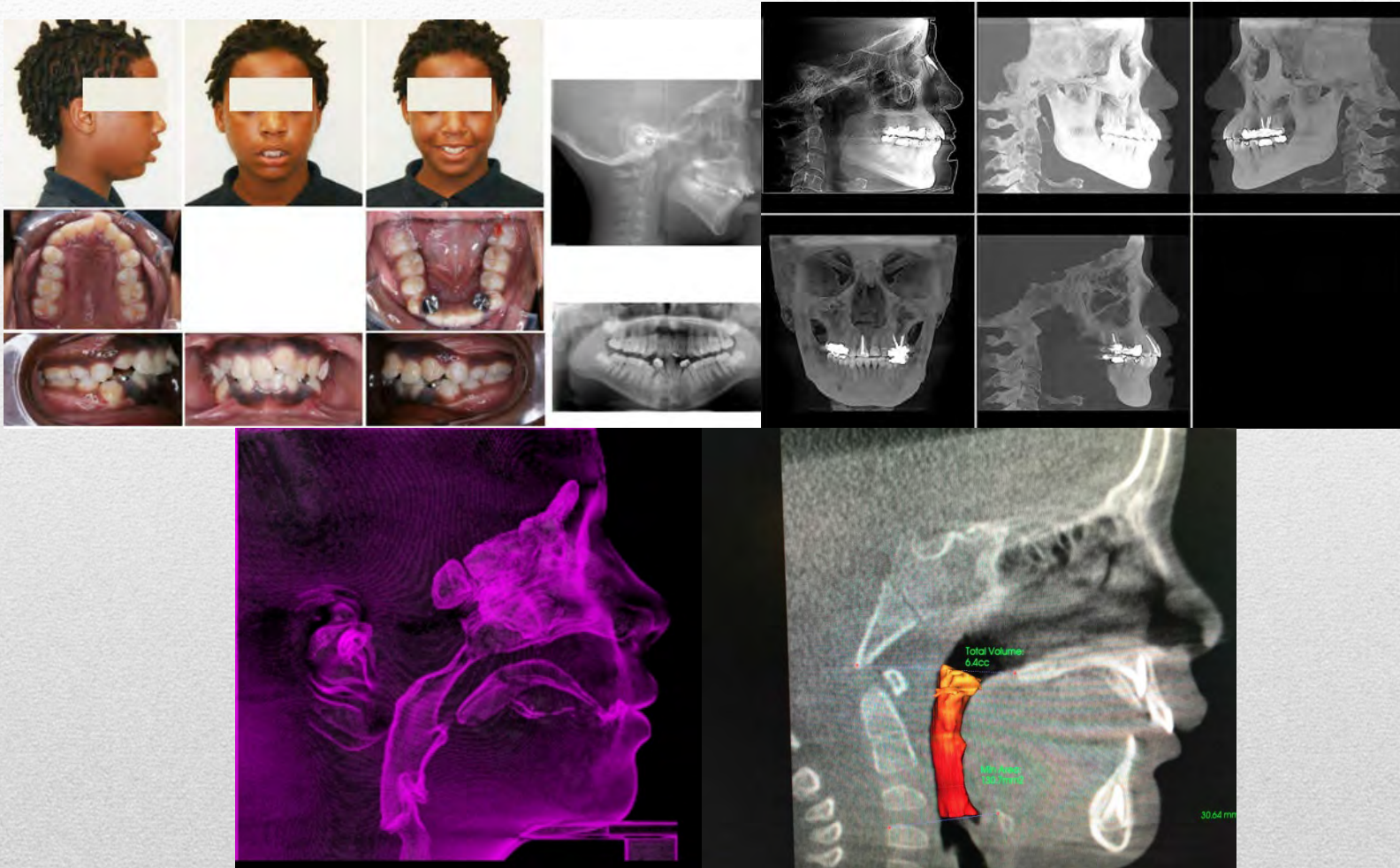


WISHFUL THINKING

POST-T&A



Multidisciplinary Team Approach



Case 3

5 year old boy with snoring, restless sleep

Bedtime wetting

Allergic rhinitis

Asthma – controlled

Family History – Allergies

Past Medical History – negative

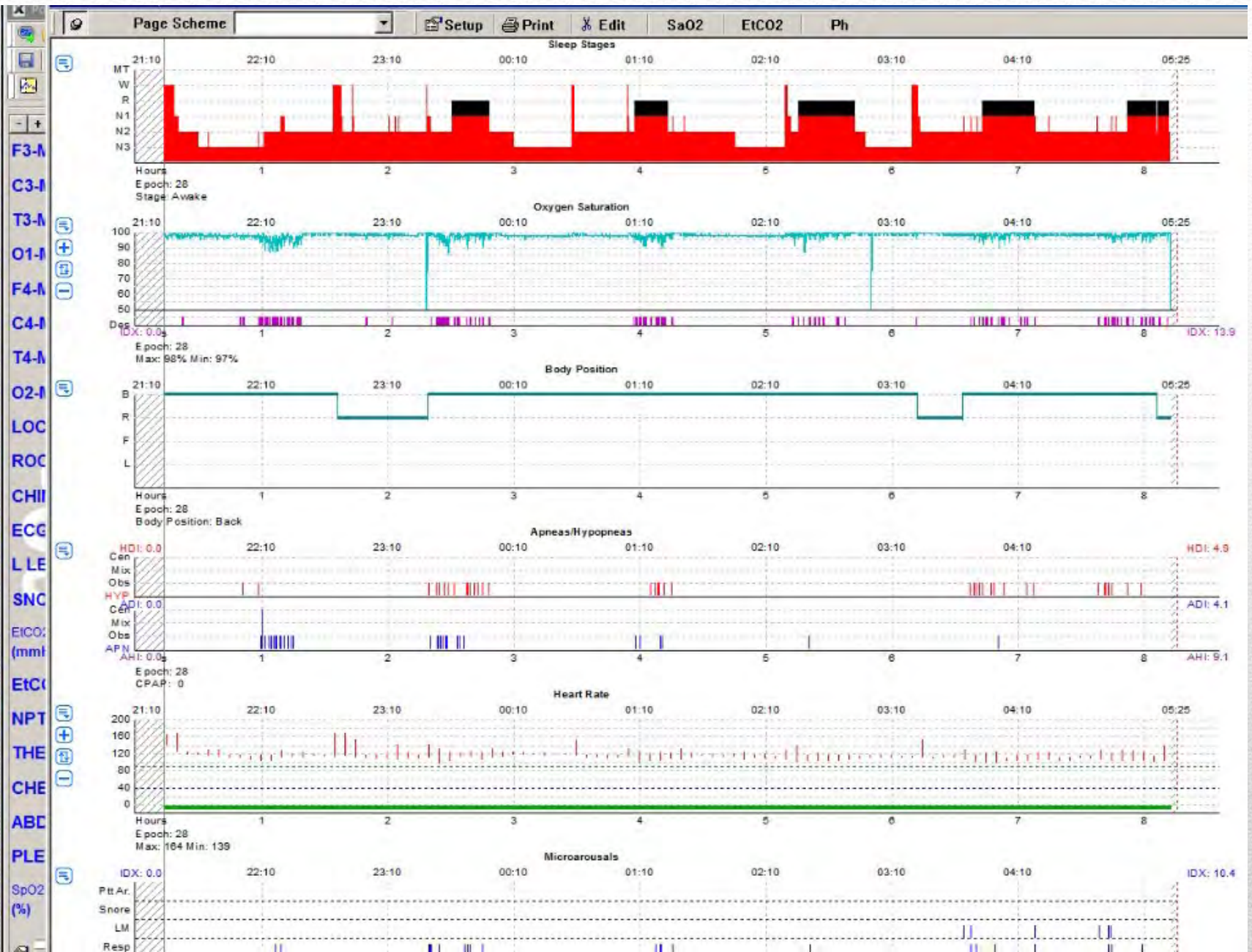
Physical Examination:

Limited nasal airflow

Retrognathia +2

Mallampati +2

Tonsils +2



OAHI: 4.7/hrTST

ODI3%: 2.8/hrTST

Resp Arousal Index: 3.5/hrTST

Treatment:

Intranasal Corticosteroid and
Oral Montelukast

Repeat PSG after 4 months

OAHI: 1.3/hrTST

ODI 3%: 0.6/hrTST

RAI: 0.8/hrTST

Case 4

6-year-old boy with snoring, restless sleep
ADHD

Family History – negative

Past Medical History – negative

Physical Examination:

Retrognathia no

Mallampati +4

Tonsils +3

6/5/12

Dx: Severe OSA (AHI-59)

S/P:T&A (AHI-30)

BEFORE

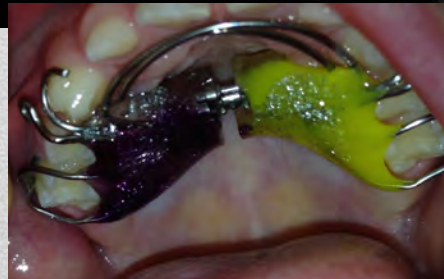


3/8/14

Dx: OSA resolved

S/P:NRO (AHI-0)

AFTER intraoral
appliance
(orthodontic plus
myofunctional)



Thank you for your attention!

